

Live surgery - 3

- Case: 6 months old Lisfranc injury right foot
- Procedure: Lisfranc fusion with plates and screws +/- Iliac crest bone grafting right foot



Brief history

- Complains of pain and swelling of **right foot** & inability to bear weight over right lower limb
- History of fall from bike 6 months back following which conservative treatment was taken
- But swelling and pain has persisted for the last 6 months. Known case of Diabetes mellitus

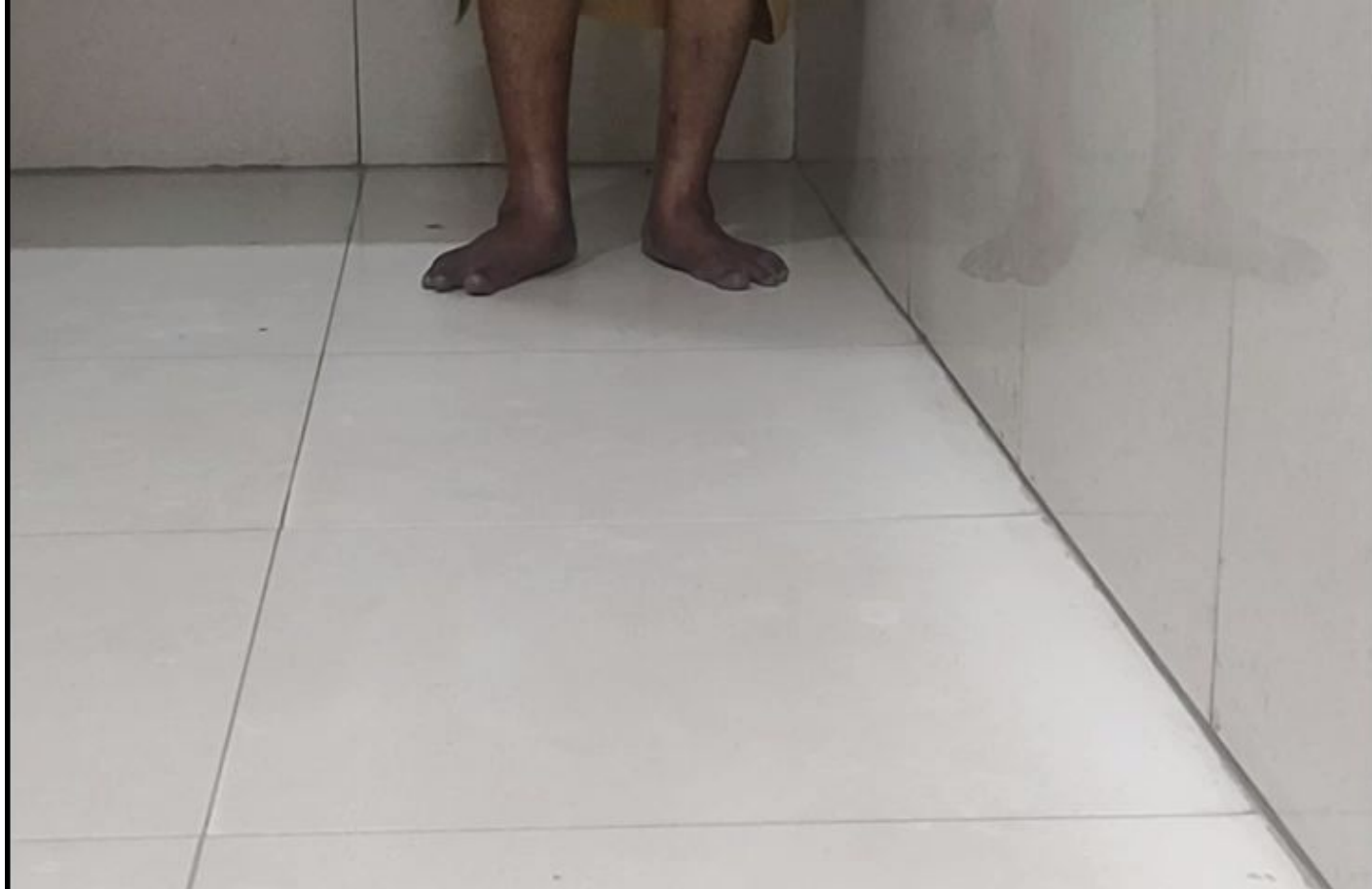Clinical examination

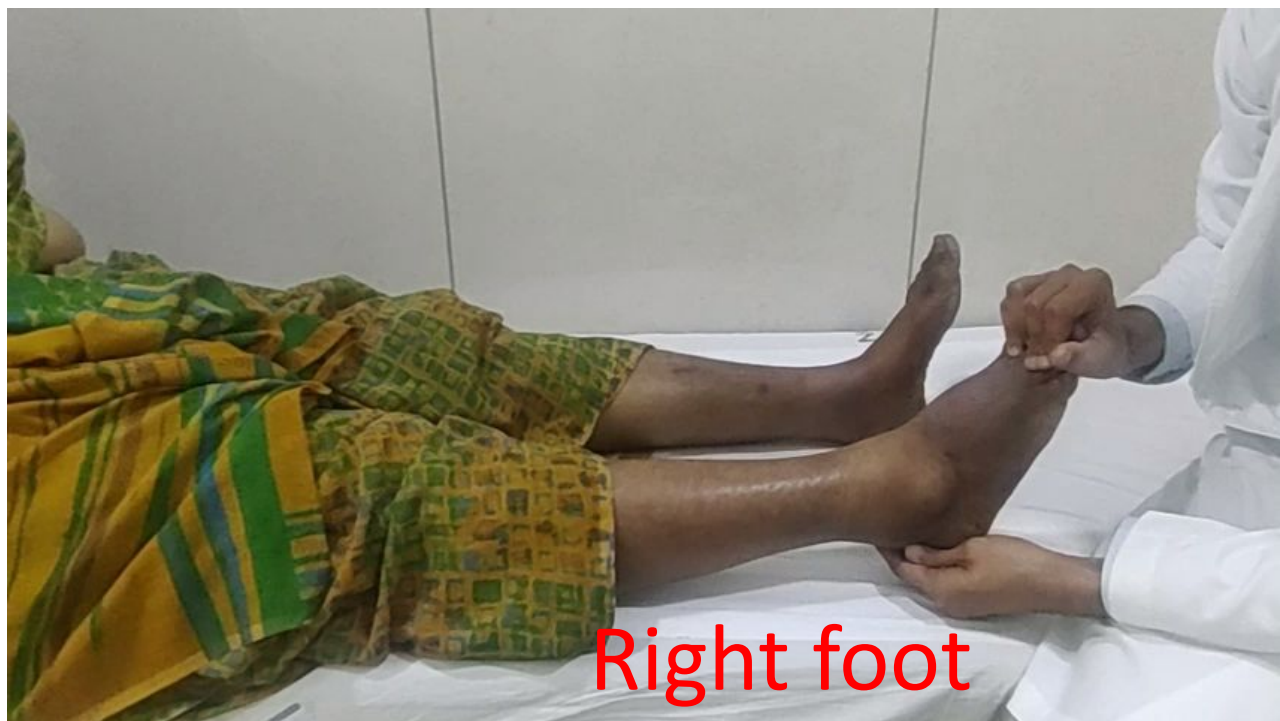Right foot

- Swelling over dorsum of right foot
- Skin condition normal
- Tenderness +
- No neurovascular deficits
- Active toe movements+
- Sensations decreased

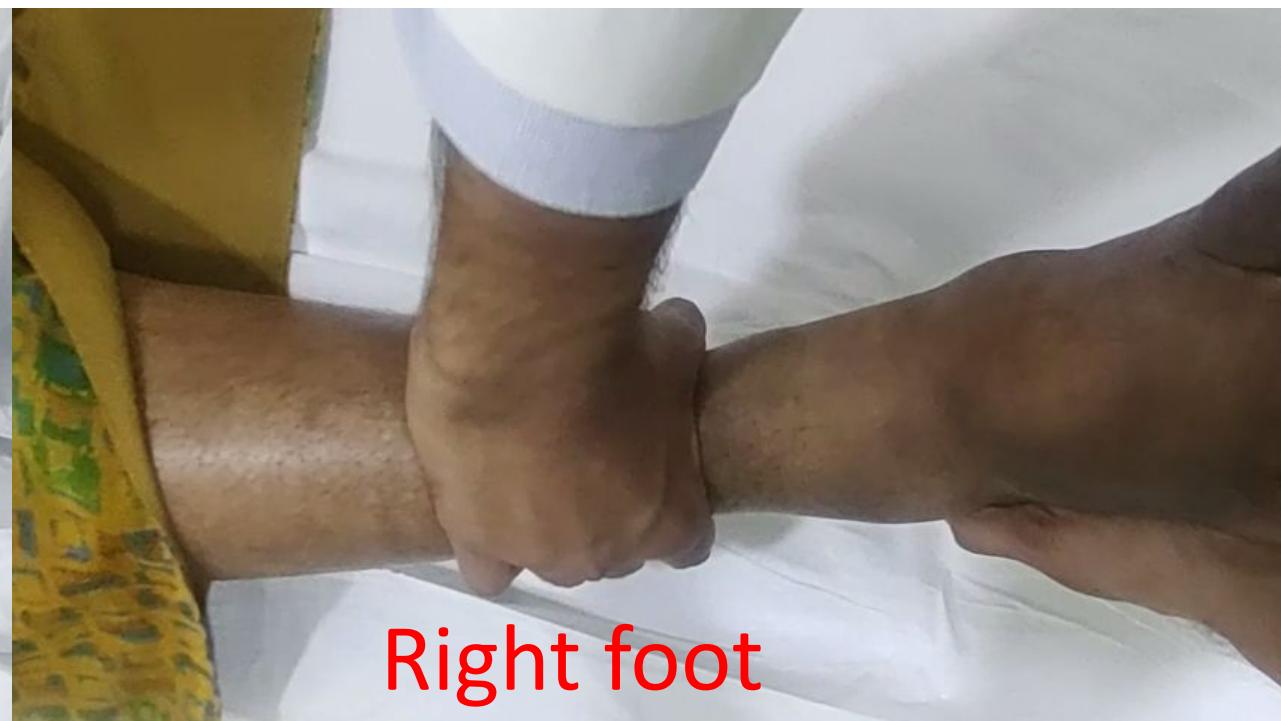Clinical video

Right foot





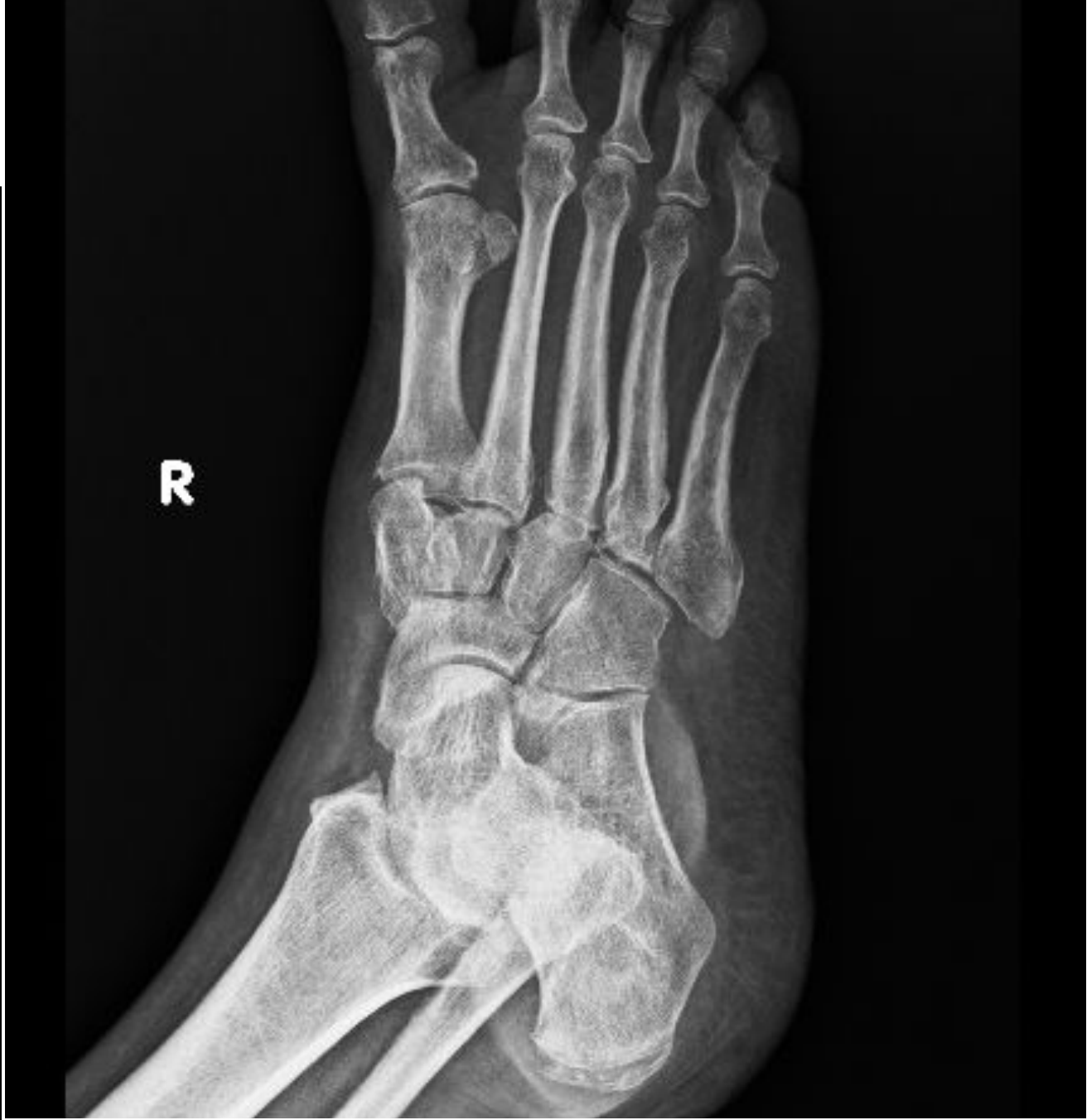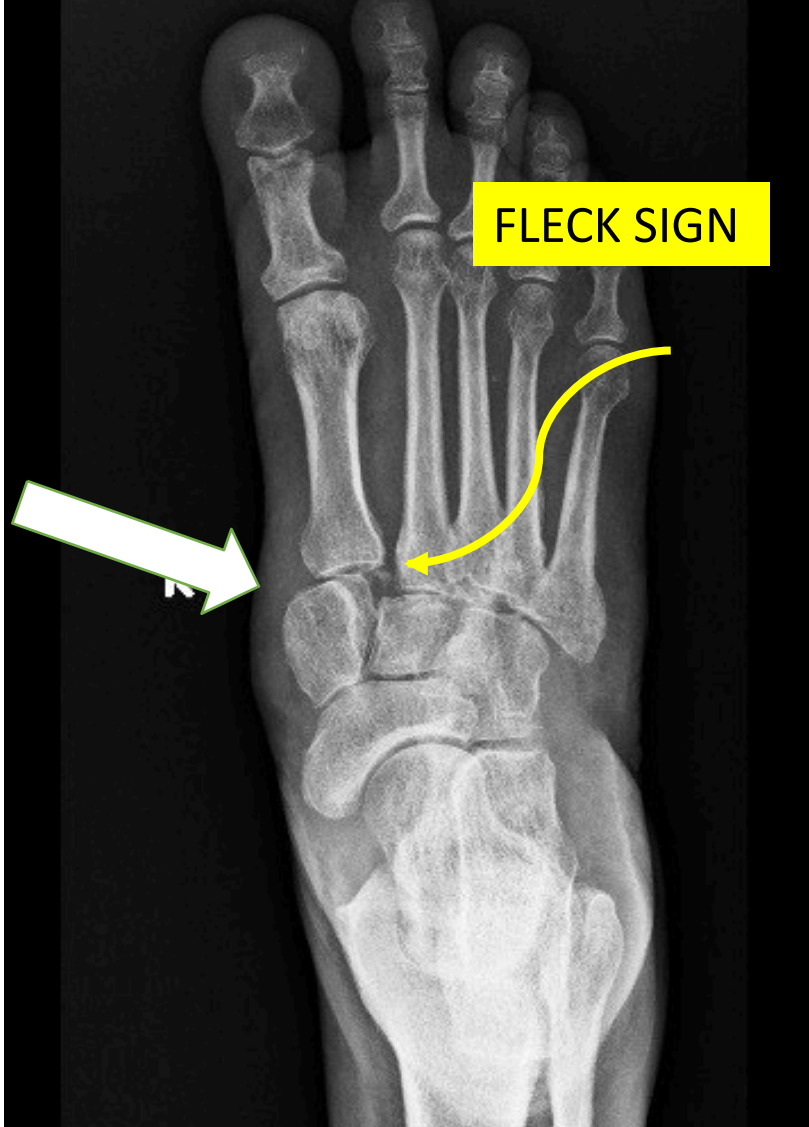Right foot

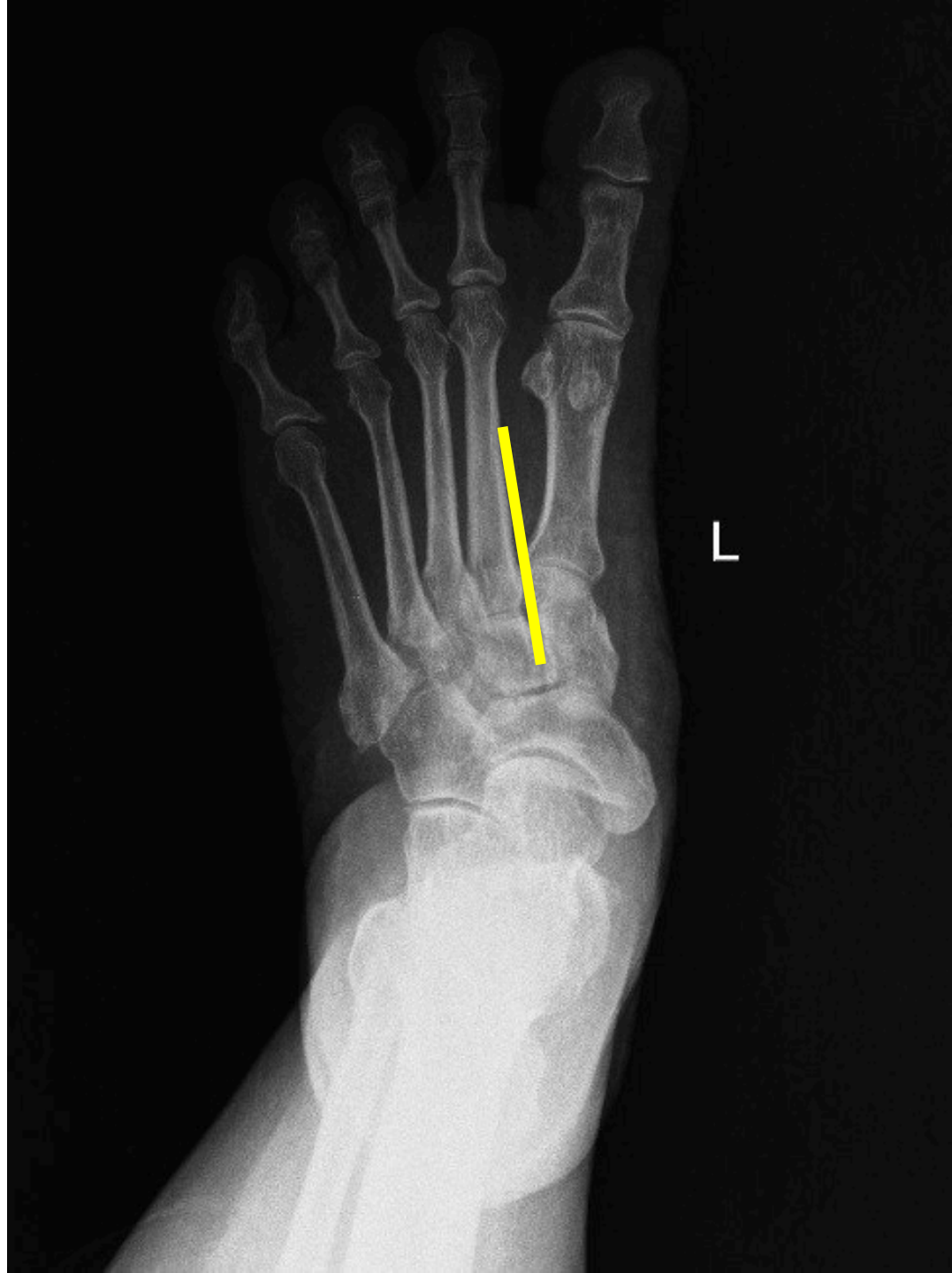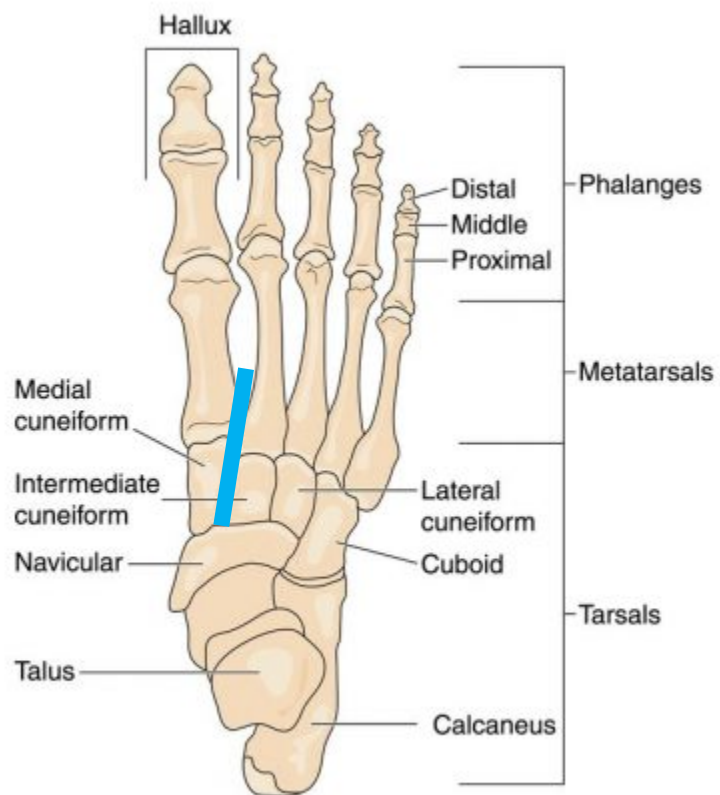


Right foot

HOMOLATERAL
TYPE

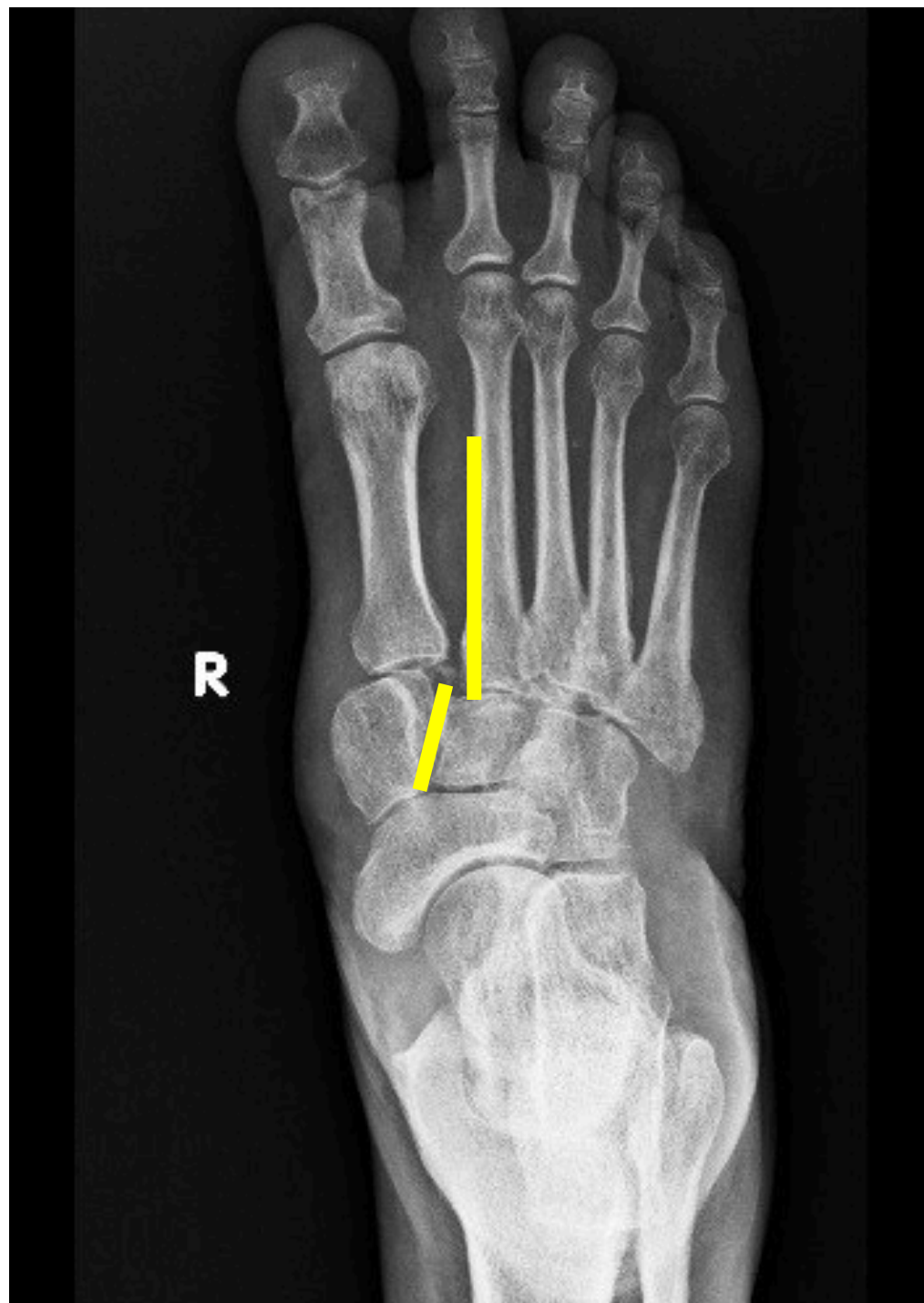LISFRANC
INJURY





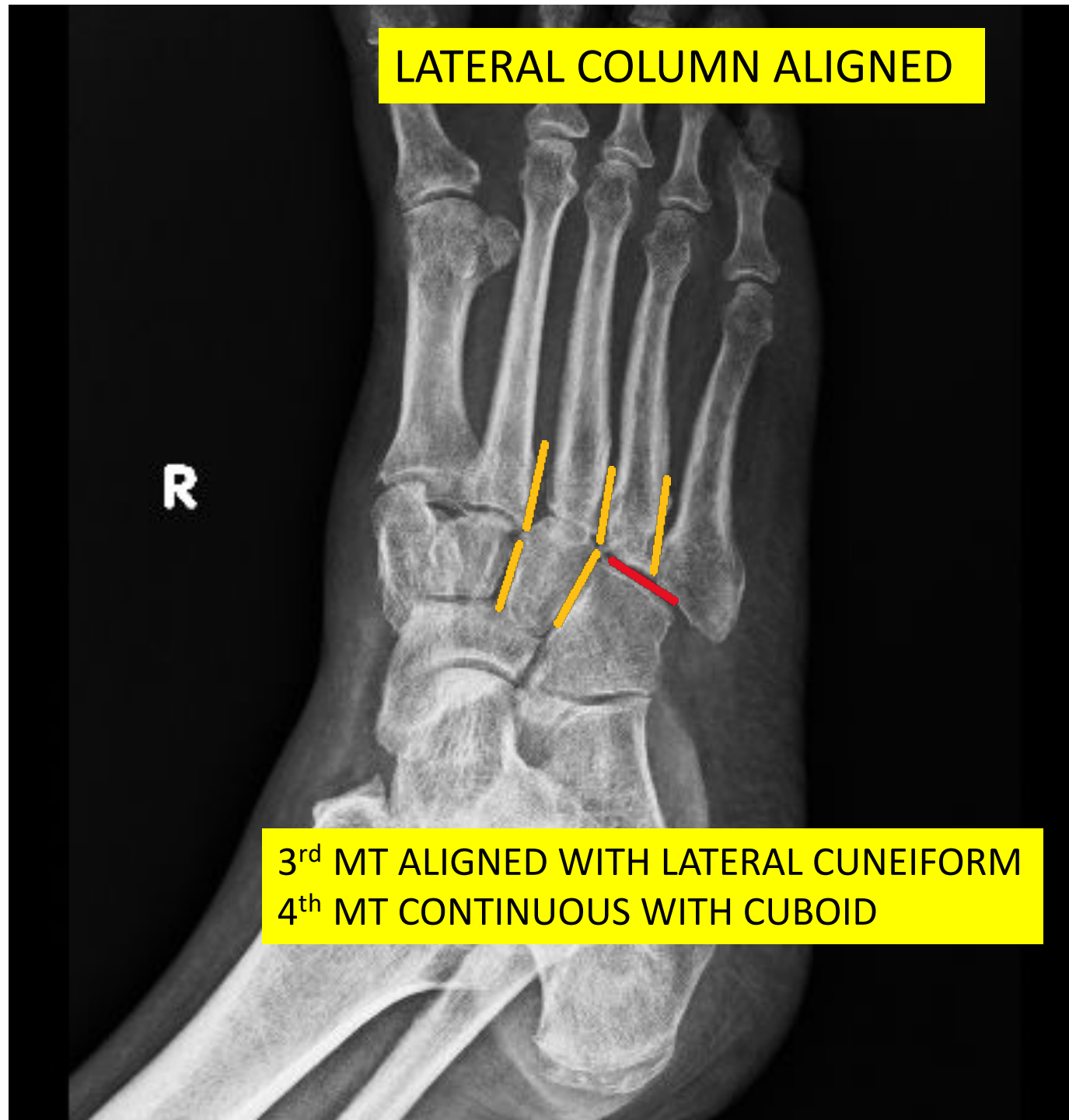
OPPOSITE
NORMAL SIDE OF
SAME PATIENT

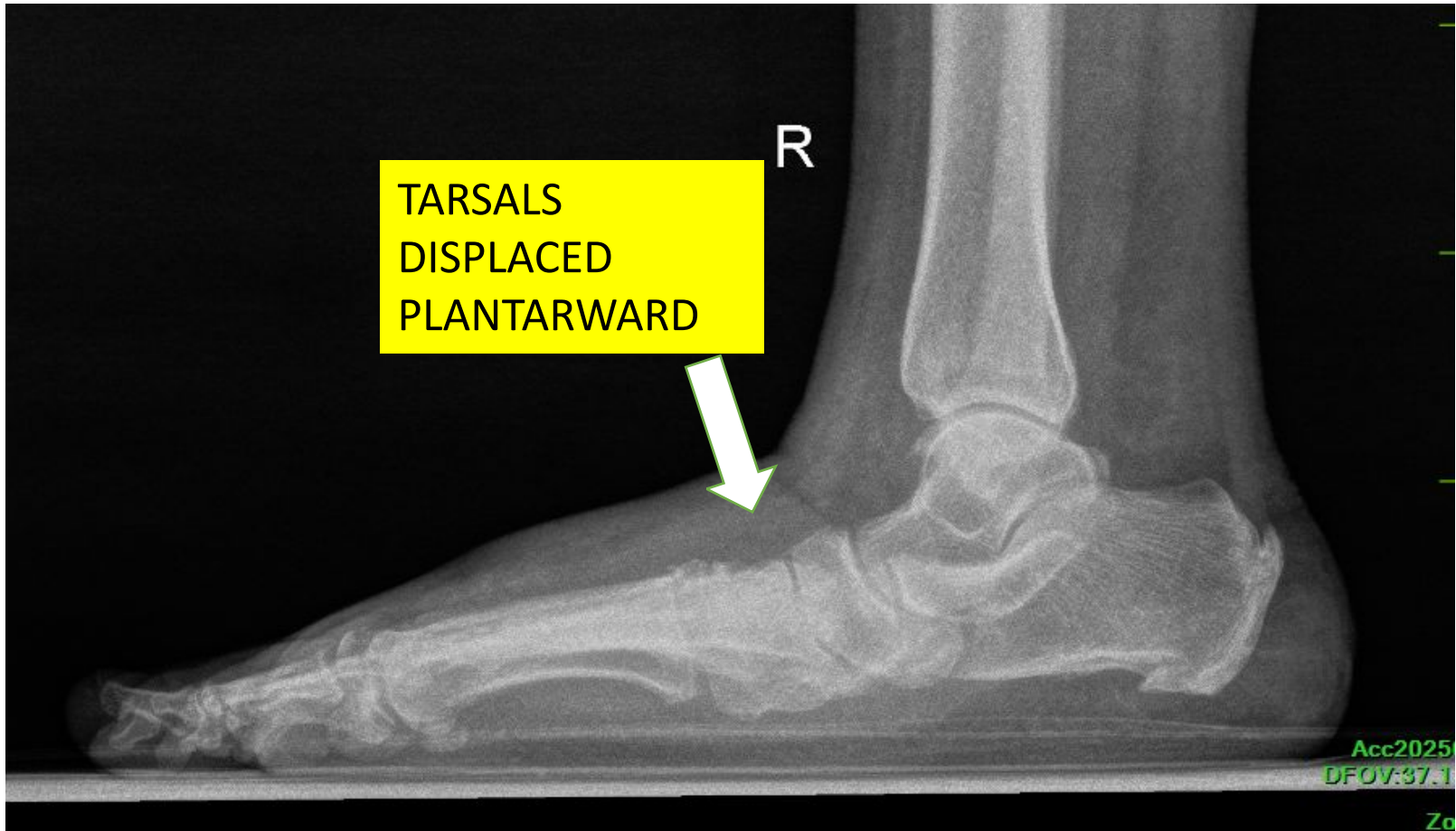
AFFECTED
SIDE



Right foot

Right foot





SAGITTAL

CORONAL

Right foot

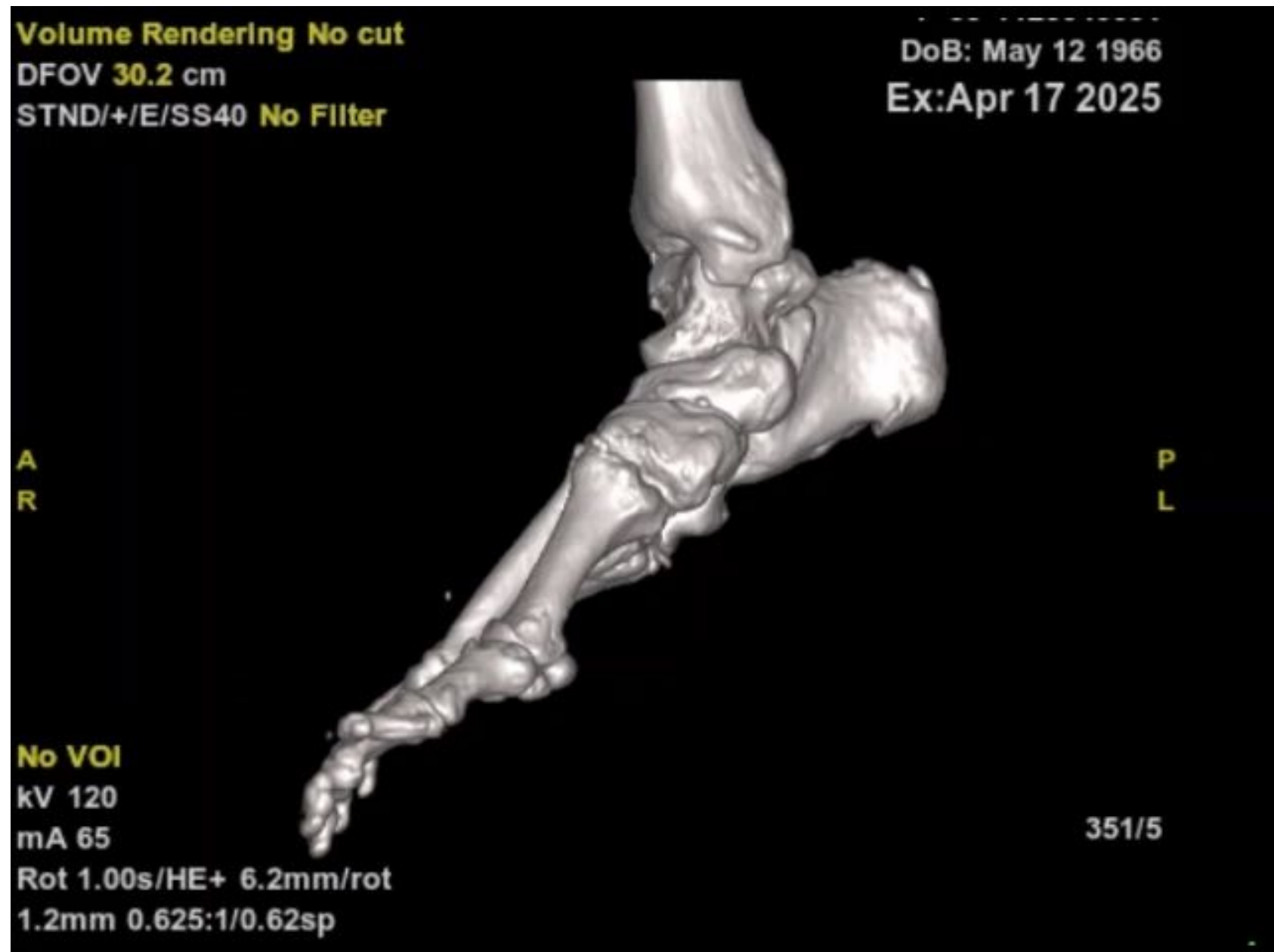**DORSAL DIPLACEMENT
OF METATARSALS**

SUBLUXED TMT JOINT

**LATERAL DISPLACEMENT
OF METATARSALS**

3D CT

Right foot



Live surgery - 3

- Surgeon: Dr Arun kamal
- Moderators :Dr Rajiv Shah, Dr Sang Gyo Seo
- Case: Lisfranc injury right foot
- Procedure: Lisfranc fusion with plates and screws right foot

